

## The Etiology of Mental Retardation in Iraqi Children

Al-Mosawi AJ<sup>1,2\*</sup>

<sup>1</sup>Department of Pediatrics and Pediatric Psychiatry, Children Teaching Hospital of Baghdad Medical City, Iraq

<sup>2</sup>Head, Iraq Headquarter of Copernicus Scientists International Panel, Iraq

### 1. Abstract

**Background:** Mental retardation is a group of heterogeneous disorders associated with generalized developmental delay during infancy and early childhood, while impairment in cognitive functions and adaptive behaviors became generally apparent during pre-school and early school years depending on the severity of the condition. Little is known about the etiology of mental retardation in Iraq. The aim of this paper is to describe the etiology of mental retardation in a sample of Iraqi children.

**Patients and methods:** During one-year period (February 2018 to February 2019), thirty-six patients with mental retardation (25 males and 11 females) were observed at the neuropsychiatry clinic at the Children Teaching hospital of Baghdad Medical City. Their ages ranged from two to seventeen years. Patients with cerebral palsy, atypical autism with mental retardation and Rett syndrome were not included in this series.

**Results:** Eighteen patients (50%) had idiopathic mental retardation (11 males and 7 females). Seven patients (19%) had Down syndrome (5 males and 2 females). Two male patients had Beckwith Wiedemann syndrome, one of them had an affected brother. Three males had inborn errors of metabolism, each one had phenylketonuria, homocystinuria and Lesch Nyhan syndrome. The patient with Lesch

Nyhan syndrome had an older brother who died from the same condition. Six patients each one had Prader-Labhart-Willi syndrome, Sanjad Sakati Richardson Kirk syndrome, Coffin Siris syndrome, kernicterus, Bartter syndrome, Pediatric Huntington disease.

Nonspecific abnormalities were present in three patients and included bilateral optic atrophy in one boy, squint and obesity in one girl and a second girl had large ears. Brain CT-scan was available for two patients with idiopathic mental retardation and one patient with kernicterus and showed normal findings.

**Conclusion:** The causes of mental retardation in about two thirds of Iraqi patients with mental retardation were idiopathic mental retardation and Down syndrome.

**2. Keywords:** Etiology; Mental retardation; Iraqi children.

### 3. Introduction

Mental retardation is a group of heterogeneous disorders associated with generalized developmental delay during infancy and early childhood, while impairment in cognitive functions and adaptive behaviors became generally apparent during pre-school and early school years depending on the

**\*Corresponding author:** Al-Mosawi AJ, Department of Pediatrics and Pediatric Psychiatry, Children Teaching Hospital of Baghdad Medical City, Iraq, E-mail: [almosawiAJ@yahoo.com](mailto:almosawiAJ@yahoo.com)

**Received Date:** June 16, 2019; **Accepted Date:** June 20, 2019;

**Published Date:** June 21, 2019

severity of the condition.

#### **Adaptive behaviors include**

Daily living skills such as feeding self, dressing/undressing and using the bathroom.

Social skills and communication skills such as understanding what is said.

Although the World Health Organization is still using the term mental retardation in its ICD-10 publication, the American Psychiatric Association has recently called the condition "Intellectual disability" [1,2].

Thomas Willis was the first doctor to describe mental retardation as a disease of the brain [1].

#### **There are two main types of mental retardation**

The syndromic mental retardation which is associated with other abnormalities caused by chromosomal and non-chromosomal genetic defects, endocrine disorders and inborn errors of metabolism.

Non-syndromic or idiopathic mental retardation is not associated with other abnormalities or underlying metabolic or endocrine disorder [1-4].

Mental retardation may also occur in various forms of cerebral palsy, bilirubin encephalopathy and atypical autism [1,4-7].

Down syndrome (Trisomy 21) is the most common type of syndromic mental retardation and the most common chromosomal disorder in humans [8].

Prader-Labhart-Willi syndrome which is also called Prader-Willi syndrome is another genetic syndrome that is associated with mental retardation. It can be caused by a deletion or disruption of genes in the proximal arm of chromosome 15 or by maternal disomy in the proximal arm of chromosome 15. However, many patients with this genetic syndrome were found to have a normal karyotype [9].

Beckwith Wiedemann syndrome is an autosomal genetic syndrome that is associated with mental retardation [10].

Inborn errors of metabolism that commonly causes mental retardation include phenylketonuria, Homocystinuria and Lesch Nyhan syndrome [11].

Phenylketonuria is an autosomal recessive inborn

error of metabolism caused by deficiency of phenylalanine hydroxylase which causes accumulation of dietary phenylalanine to potentially toxic levels.

Homocystinuria is another an autosomal recessive inborn error of metabolism associated with mental retardation. It is caused by deficiency of cystathionine beta synthase deficiency or CBS deficiency.

Lesch Nyhan syndrome is an X-linked inborn error of purine metabolism associated with mental retardation. It is caused by deficiency of hypoxanthine-guanine phosphoribosyl transferase enzyme which is normally present in each cell in the body, but its highest concentration is in the brain, especially in the basal ganglia [11].

Other rare causes of mental retardation include Sanjad Sakati Richardson Kirk Syndrome, Coffin Siris syndrome, Bartter syndrome, pediatric Huntington disease and bilirubin encephalopathy, kernicterus [4,12-18].

#### **4. Patients and Methods**

During one-year period (February 2018 to February 2019), thirty-six patients with mental retardation (25 males and 11 females) were observed at the neuropsychiatry clinic at the Children Teaching hospital of Baghdad Medical City. Their ages ranged from two to seventeen years.

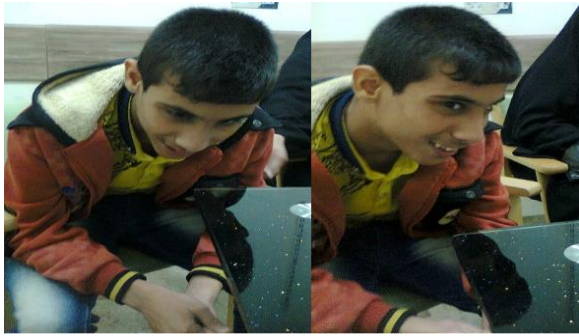Patients with cerebral palsy, atypical autism with mental retardation and Rett syndrome were not included in this series.

Nonspecific abnormalities were present in three patients and included bilateral optic atrophy in one boy, squint and obesity in one girl and a second girl had large ears.

Brain CT-scan was available for two patients with idiopathic mental retardation and one patient with kernicterus and showed normal findings.

#### **5. Results**

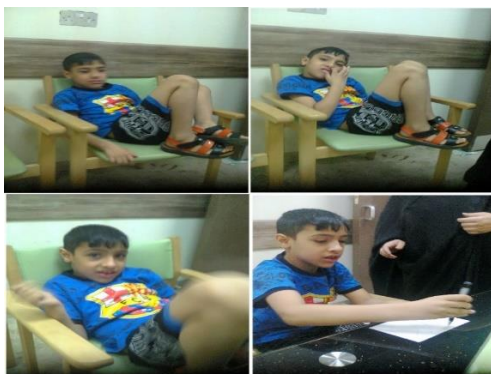Eighteen patients (50%) had idiopathic mental retardation, eleven of them were males and seven were females.



**Figure 1:** Fourteen-year old boy with idiopathic mental retardation and bilateral optic atrophy. He had delayed motor development and walked after 18 months and still had some difficulty in climbing stairs. He started babbling at about the age of four years and he still had very poor speech with limited vocabulary and could say few two-word sentences mostly to express needs. He could control bowel motions, but he needed help at toilet as he couldn't clean self properly and couldn't wash hands. He couldn't dress self properly. Despite his marked developmental retardation, he was willing to interact with the doctor, he greeted the doctor and shook hand. He looked awkward when he sat on the chair. However, he had good eye contact and he rapidly obeyed the doctor when asked him to take the pen to copy a line and a circle, but he could copy nothing, he just touched the pen with paper. His CT-scan showed normal findings.



**Figure 2:** Two years and five months old girl. She was obese (Weight was 22 Kg), hypotonic and unable to stand and had squint of the left eye. She was not saying any word. She was thought initially to have Prader Willi syndrome, but pelvic ultrasound showed normal size uterus and ovaries. Brain CT-scan showed normal findings.




**Figure 3:** An eight-year-old boy with idiopathic mental retardation

and poor speech development. He showed inappropriate behavior and was spilling when drinking from cup or eating with spoon. He was disobedient and refused to sit appropriately on the chair. He was unable to hold a pen correctly and was unable to copy a straight line or a circle.




**Figure 4:** An eleven-year girl with idiopathic mental retardation. She has large ears and she could copy a circle and a square, but she couldn't copy a good triangle and a diamond. show patients with idiopathic mental retardation.

Seven patients (19%) had Down syndrome, five of them were males and two were girls. Karyotype was available for two patients with Down syndrome and showed (47XY+21).



**Figure 5:** An eight-year boy with Down syndrome. He was social, but hyperactive and liked to scribble. He copies a line but couldn't copy a circle.





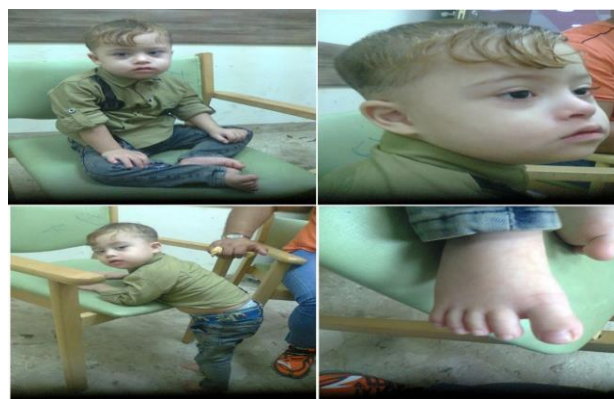**Figure 6:** A thirteen-year old boy with Down syndrome. He could copy a line and a circle, but he couldn't copy a square.



**Figure 7:** A four-year boy with Down syndrome. Karyotype: 47XY +21. He was not speaking and couldn't copy a circle.



**Figure 8:** A ten-year old girl with Down syndrome. She could copy a circle and a square, but she couldn't copy a triangle. She couldn't stand momentarily on one foot without holding furniture.



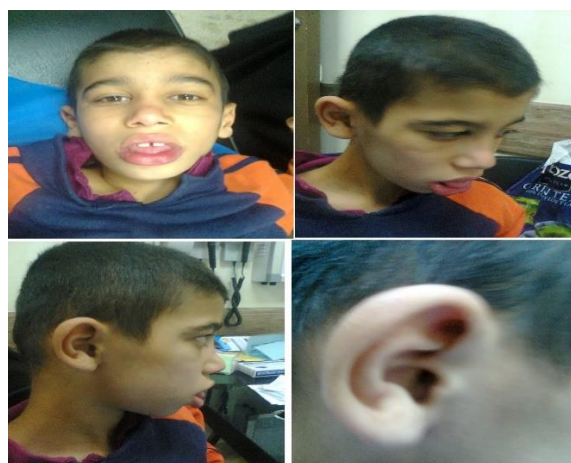**Figure 9:** A three-year old boy with Down syndrome. He had delayed speech and delayed motor development and he was unable to stand alone.



**Figure 10:** A boy and girl with Down syndrome and delayed motor development and speech. The girl had single palmar crease.

**Figure 5-10** show patients with Down syndrome.

Two male patients had Beckwith Wiedemann syndrome, one of them **Figure-11** had an affected brother.



**Figure 11:** A boy with Beckwith Wiedemann syndrome who had mental retardation, macroglossia, hepatomegaly and recurrent hypoglycaemia.




Three males had inborn errors of metabolism. One patient had phenylketonuria,



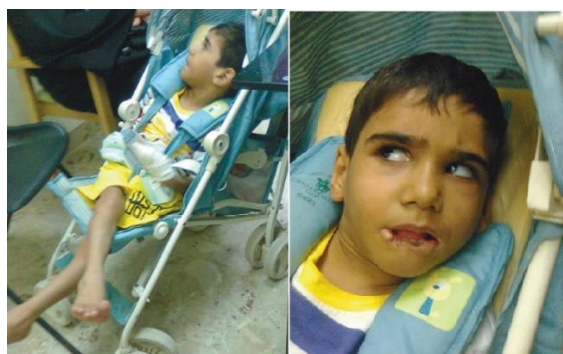**Figure 12:** A boy with phenylketonuria and delayed institution of dietary restriction. He had light hair, hyperactivity and history of seizures.

one patient had homocystinuria



**Figure 13:** A ten-year boy with homocystinuria. He had posterior dislocation of the lens of the right eye and markedly elevated serum methionine. He couldn't copy a straight line.

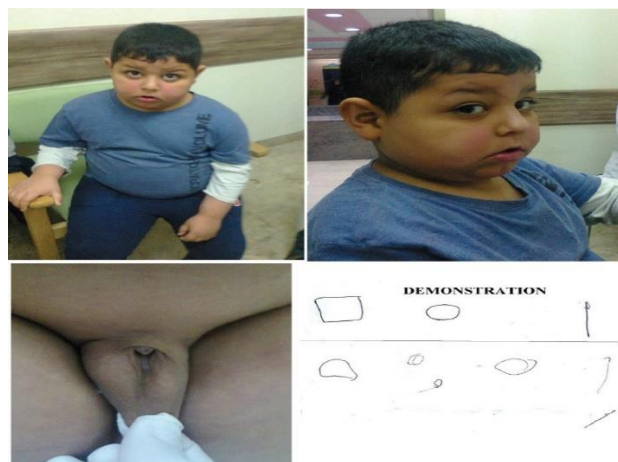and one patient had Lesch Nyhan syndrome



**Figure 14:** A nine-year old boy with Lesch Nyhan syndrome. His older brother died at the age of 14 years from the same condition. He had spasticity with scissoring of the lower limbs, choreoathetosis, self-mutilation with biting of the lips and hands, hyperuricemia and renal stones.

The patient with Lesch Nyhan syndrome had an older brother who died from the same condition.

One male patient had Prader-Labhart-Willi syndrome



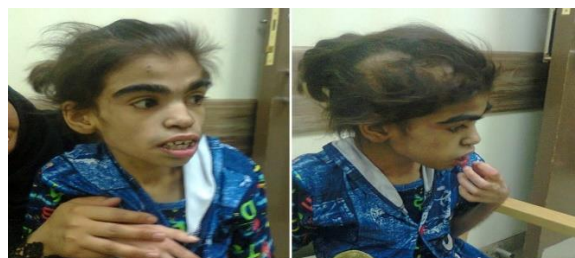**Figure 15:** A seven-year old boy with Prader-Labhart-Willi syndrome. He had characteristic facial appearance, obesity, hypogonadism. He could copy a line and a circle of poor quality, but he couldn't copy a square.

One male patient had Sanjad Sakati Richardson Kirk syndrome



**Figure 16:** An eight-year old boy with Sanjad-Sakati-Richardson-Kirk. He had chronic hypocalcemia, micrognathia, deep set eyes, thin lips, long philtrum and beaked nose.

One female patient had Coffin Siris syndrome



**Figure 17:** A twelve-year old girl with Coffin Siris syndrome. She had feeding difficulties, growth retardation and characteristic dysmorphic facial features including thick eyebrows, depressed and wide nasal bridge, low set ears, large mouth with thick everted upper and lower lips. Despite having hypertrichosis and hirsutism, she has area of hair loss.

One male patient had Kernicterus.

One female patient had Bartter syndrome with low set ears.

One male patient had Pediatric Huntington disease, this patient was the older one, aged 17 years and the only one who died.

## 6. Discussion

Mental retardation is a complex heterogeneous condition and the comparison between various studies of the etiology of mental retardation is rather difficult because of the variable inclusion criteria.

Recently emphasis has been made that in only a proportion of patients with mental retardation an accurate etiologic diagnosis can be made [19]. In this study half of the Iraqi patients had a diagnosis of idiopathic mental retardation.

Cabarcas and colleagues (2013) found a definitive etiology of mental retardation in 64.4% of their patients [19], while in this study a definitive etiology of mental retardation was found in 50%.

In this study, patients with cerebral palsy, atypical autism with mental retardation and Rett syndrome were not included because of the following reasons:

Atypical autism, a pervasive developmental disorder is mostly categorized differently from mental retardation [1] and its inclusion may cause some confusion. Motor impairment in cerebral palsy may lead to significant developmental delay with inaccurate diagnosis of mental retardation despite the lack of significant cognitive impairment.

Cabarcas and colleagues (2013) inclusion of cases of cerebral palsy caused by perinatal hypoxia made the percentage of genetic causes of mental retardation 23.8% [19], which is much less than the percentage of genetic causes of mental retardation in this study which was 47%.

In this study have of the patients had idiopathic mental retardation was the most common diagnosis, however, the inclusion of patients with cerebral palsy is expected to significantly reduce its percentage as a cause of mental retardation.

We agree with the recently expressed opinion Cabarcas and colleagues (2013) that the percentage of idiopathic mental retardation could be lower if patients had more genetic.

## 7. Conclusion

The causes of mental retardation in about two thirds of Iraqi patients with mental retardation were idiopathic mental retardation and Down syndrome.

## 8. Acknowledgment

Gratitude us expressed for all the parents of the patients for their approval to publish the photos in the article.

## References

1. [Al-Mosawi AJ. Pediatric psychiatry: An accredited training course. \(ed\). Saarbrücken: LAP Lambert Academic Publishing \(Germany\); 2018.](#)
2. [Al-Mosawi AJ. A novel therapeutic approach for idiopathic mental retardation. \(ed\). Saarbrücken: LAP Lambert Academic Publishing \(Germany\); 2018.](#)
3. [Al-Mosawi AJ. The syndrome of childhood hypoparathyroidism, vitiligo, poliosis and macrocytic anemia. \(ed\). Saarbrücken: LAP Lambert Academic Publishing \(Germany\); 2018.](#)
4. [Al-Mosawi AJ. A novel therapeutic approach for kernicterus. \(ed\). Saarbrücken: LAP Lambert Academic Publishing \(Germany\); 2018.](#)
5. [Al-Mosawi AJ. A novel therapeutic approach for the treatment of cerebral palsy. \(ed\). Saarbrücken: LAP Lambert Academic Publishing \(Germany\); 2017.](#)
6. [Al-Mosawi AJ. A novel therapeutic approach for the treatment of brain atrophy \(ed\). Saarbrücken: LAP Lambert Academic Publishing \(Germany\); 2017.](#)
7. [Al-Mosawi AJ. Asperger syndrome and regressive autism. \(ed\). Saarbrücken: LAP Lambert Academic Publishing \(Germany\); 2018.](#)
8. [Al-Mosawi AJ. Down syndrome Atlas. \(ed\). Saarbrücken: LAP Lambert Academic Publishing \(Germany\); 2018.](#)

9. [Al-Mosawi AJ. Prader-Labhart-Willi syndrome. \(ed\). Saarbrücken: LAP Lambert Academic Publishing \(Germany\); 2018.](#)
10. [Al-Mosawi AJ. Beckwith Wiedemann syndrome. \(ed\). Saarbrücken: LAP Lambert Academic Publishing \(Germany\); 2018.](#)
11. Al-Mosawi AJ. Lesch Nyhan syndrome. (ed). Saarbrücken: LAP Lambert Academic Publishing (Germany); 2018.
12. [Al-Mosawi AJ. Rare genetic disorders in Iraq. \(ed\). Saarbrücken: LAP Lambert Academic Publishing \(Germany\); 2011.](#)
13. [Al Mosawi AJ. Unilateral renal agenesis associated with the 76th case of Coffin Siris syndrome in the world. \*Pediatr Nephrol\* 2006; 21: 1564.](#)
14. [Al-Mosawi AJ. Genetic drift. Letter from Baghdad: Coffin-Siris syndrome in a girl with absent kidney. \*Am J Med Genet A\*. 2006; 140: 1789-1790.](#)
15. [Al-Mosawi AJ. Coffin Siris syndrome. \(ed\). Saarbrücken: LAP Lambert Academic Publishing \(Germany\); 2018.](#)
16. [Al-Mosawi AJ. Classical pediatric Bartter syndrome with low set ears. \(ed\). Saarbrücken: LAP Lambert Academic Publishing \(Germany\); 2018.](#)
17. Al-Mosawi AJ. Pediatric Huntington disease. (ed). Saarbrücken: LAP Lambert Academic Publishing (Germany); 2018.
18. [Al-Mosawi AJ. Sanjad Sakati Richardson Kirk Syndrome. \(ed\). Saarbrücken: LAP Lambert Academic Publishing \(Germany\); 2019.](#)
19. [Cabarcas L, Espinosa E, Velasco H. Etiology of mental retardation in children: experience in two third level centers. \*Biomedica\*. 2013; 33: 402-410.](#)

---

**Citation:** Al-Mosawi AJ. The Etiology of Mental Retardation in Iraqi Children. *SunKrist J Neonat Pediatr*. 2019; 1: 1001.

**Copy Right:** © 2019 Aamir Jalal Al Mosawi. This is an open-access article distributed under the terms of the Creative Commons Attribution License, which permits unrestricted use, distribution and reproduction in any medium, provided the original author and source are credited.